

Anatomical study of zygomaticotemporal nerve: Clinical implications for surgical treatment of migraine headache in Thai population

Chutima Jirapinyo*

Seree lamphongsai**

Jirapinyo C, lamphongsai S. Anatomical study of zygomaticotemporal nerve: Clinical implications for surgical treatment of migraine headache in Thai population. Chula Med J 2018 Jul – Aug; 62(4): 667 - 74

Background : *Migraine headache is one of the most common neurovascular disorders that is often inadequately treated by currently available medical therapies. Clinical evidences have shown that the decompression of peripheral nerve trigger points is successful in migraine relief. The nerve responding to the temporal trigger site is the zygomaticotemporal branch of the trigeminal nerve.*

Objectives : *This cadaveric study of the anatomy of the zygomaticotemporal nerve was undertaken to delineate where this nerve exits the deep temporal fascia in relation to the plane through the superior border of tragus and the zygomaticofrontal suture.*

Methods : *The temporal region of twenty-two fresh cadaveric hemiheads were dissected through bicoronal incision. Points of measurement where the zygomaticotemporal nerve exits the deep temporal fascia in relation to the plane through the superior border of tragus and the zygomaticofrontal suture were recorded.*

* Princess Sirindhorn Craniofacial Center, King Chulalongkorn Memorial Hospital, Bangkok, Thailand

** Department of Surgery, Faculty of Medicine, Chulalongkorn University

Results : *The piercing point of the zygomaticotemporal nerve was located 27.0 ± 3.7 mm from the zygomaticofrontal suture, 3.9 ± 4.7 mm superior to the plane through the superior border of tragus and the zygomaticofrontal suture (HL), and 25.6 ± 3.7 mm lateral to the plane through the zygomaticofrontal suture and perpendicular to HL. No significant difference between the right and left sides was detected.*

Conclusions : *The nerve responding for the temporal trigger site in migraine headache is the zygomaticotemporal branch of the trigeminal nerve. Surgical decompression or chemodenervation of the surrounding temporalis can help alleviate the symptoms of migraine headache. Advances in the understanding of detailed anatomical information will enhance the safety and effectiveness of migraine surgery and botulinum toxin A injection treatment.*

Keywords : *Zygomaticotemporal nerve, migraine headache, surgical treatment of migraine headache, forehead surgery, botulinum toxin injection.*

Correspondence to: Jirapinyo C. Princess Sirindhorn Craniofacial Center, King Chulalongkorn Memorial Hospital, Bangkok 10330, Thailand.

Received for publication. January 14, 2018.

ชุตินา จิรภิญโญ, เสรี เอี่ยมผ่องใส. การศึกษาโครงสร้างทางกายวิภาคของเส้นประสาทไซโกมาติโคเทมพอรอลเพื่อประโยชน์ในการรักษาโรคปวดศีรษะไมเกรนในประเทศไทย. จุฬาลงกรณ์เวชสาร 2561 ก.ค. - ส.ค.;62(4): 667 - 74

- เหตุผลของการทำวิจัย** : โรคปวดศีรษะไมเกรนเป็นโรคที่พบบ่อยและการรักษาด้วยยา ในปัจจุบันการศึกษายังได้ผลไม่ดีพอ จากหลักฐานทางการแพทย์พบว่าการผ่าตัดเพื่อคลายการบีบรัดเส้นประสาทไซโกมาติโคเทมพอรอลซึ่งเป็นแขนงของเส้นประสาทสมองคู่ที่ห้า ทำให้สามารถรักษาอาการปวดศีรษะไมเกรนได้ดีขึ้น
- วัตถุประสงค์** : เพื่อศึกษาโครงสร้างทางกายวิภาคเพื่อค้นหาตำแหน่งของเส้นประสาทไซโกมาติโคเทมพอรอล และความสัมพันธ์กับตำแหน่งกายวิภาคข้างเคียง
- วิธีการทำวิจัย** : ศึกษาในอาจารย์ใหญ่จำนวน 22 ซีกของศีรษะส่วนเทมพอรอลผ่านทางแผลไบโคโรนอลโดยวัดตำแหน่งจุดที่เส้นประสาทไซโกมาติโคเทมพอรอล ออกจากเทมพอรอลฟาสเซียชั้นลึกเทียบกับตำแหน่งทรากัสและตำแหน่งรอยต่อของกระดูกโคนกแกมและกระดูกหน้าผาก
- ผลการศึกษา** : ตำแหน่งที่เส้นประสาทไซโกมาติโคเทมพอรอลออกจากเทมพอรอลฟาสเซียชั้นลึกอยู่ที่ 27.0 ± 3.7 มิลลิเมตร จากตำแหน่งรอยต่อของกระดูกโคนกแกมและกระดูกหน้าผาก และ 3.9 ± 4.7 มิลลิเมตร สูงจากเส้นสมมติจากตำแหน่งทรากัสไปยังรอยต่อของกระดูกโคนกแกมและกระดูกหน้าผาก และ 25.6 ± 3.7 มิลลิเมตร จากเส้นสมมุติที่ตั้งฉากกับเส้นสมมุติแรกออกมาทางด้านข้าง โดยไม่พบความแตกต่างอย่างมีนัยสำคัญทางสถิติระหว่างข้างซ้ายและข้างขวา
- สรุป** : เส้นประสาทที่ส่งผลต่อการปวดศีรษะไมเกรนบริเวณขมับ คือเส้นประสาทเส้นประสาทไซโกมาติโคเทมพอรอล การผ่าตัดเพื่อคลายการหดรัดกล้ามเนื้อรอบเส้นประสาท หรือการฉีดสารคลายกล้ามเนื้อบริเวณกล้ามเนื้อรอบ ๆ สามารถช่วยบรรเทาอาการปวดศีรษะไมเกรนได้ ดังนั้นการเข้าใจรายละเอียดทางกายวิภาคของเส้นประสาทนี้สามารถช่วยให้การผ่าตัดรักษาอาการปวดศีรษะไมเกรนได้ดีขึ้น
- คำสำคัญ** : ปวดศีรษะ, ไมเกรน, เส้นประสาทไซโกมาติโคเทมพอรอล, การผ่าตัดรักษาไมเกรน, การผ่าตัดบริเวณหน้าผาก, การฉีดสารโบทูลินัม.

Migraine headache is one of the most common neurovascular disorders that is often inadequately treated by available medical therapies, resulting in majority of patients with significant residual disabilities. It was found that a number of patients who had chronic migraine headache had improvement of their condition following forehead rejuvenation surgery. Hence, the possibility of permanent migraine relief through surgical resection of the zygomaticotemporal nerve was postulated.^(1,2) Clinical evidence has shown that the decompression of the peripheral nerve trigger points is successful in migraine relief. In the past decade, surgical techniques have been developed and subsequently resulted in clinical improvement that was more complete and more durable.^(3,4) Four major extracranial trigger sites (frontal, temporal, occipital and nasoseptal) have been recently identified, and decompression of these peripheral trigger sites has been shown to significantly improve the symptoms.⁽³⁾

The nerve responding to the temporal trigger site is the zygomaticotemporal branch of the trigeminal nerve. Several studies have showed that this branch is the culprit in some migraines, and botulinum toxin injection of the temporalis in the region of its exit from the deep temporal fascia has been shown to be clinically effective.^(2,4-6) However, in order to perform safe and effective forehead rejuvenating surgery or migraine surgery, a thorough knowledge of the anatomy of the temporal area is essential.

This cadaveric study of the detailed anatomy of the zygomaticotemporal nerve will delineate where this nerve exits the deep temporal fascia in relation to the plane through the superior border of tragus and the zygomaticofrontal suture.

Materials and Methods

Twelve fresh cadaveric heads were acquired from the Department of Anatomy of the Faculty of Medicine, Chulalongkorn University, Bangkok, Thailand. None of the specimens had a history of trauma or surgery to the head and neck area or any craniofacial anomalies. The temporal region of the twenty-four fresh cadaveric hemiheads were dissected through bicoronal incision. Photographs of the relevant points were taken. Points of measurement where the zygomaticotemporal branch exits the deep temporal fascia in relation the plane through the superior border of tragus and the zygomaticofrontal suture were recorded.

The following two reference planes were established to enable accurate recording of the piercing location of the zygomaticotemporal branch of the trigeminal nerve:

- 1) A horizontal reference line (HL): the plane through the superior border of tragus and the zygomaticofrontal suture; and
- 2) A vertical reference line (VL): the plane through the zygomaticofrontal suture perpendicular to the HL.

All numerical data were processed using Microsoft Excel 2010 (Microsoft Corp., Redmond, WA, USA) and SPSS version 22.0.0.0 (IBM Corp., Armonk, NY, USA) and are presented as mean \pm standard deviation values. Paired *t*-test was used to compare the data from the right and left sides.

Results

The piercing point of the zygomaticotemporal nerve was located 27.0 ± 3.7 mm from the zygomaticofrontal suture, 3.9 ± 4.7 mm superior to the plane

(HL) through the superior border of tragus and the zygomaticofrontal suture, and 25.6 ± 3.7 mm lateral to the plane (VL) through the zygomaticofrontal suture and perpendicular to the HL (Figure 1 and Table 1). On the right side, The piercing point of the zygomaticotemporal nerve was located 26.7 ± 3.2 mm from the zygomaticofrontal suture, 4.4 ± 4.6 mm superior to the plane (HL) through the superior border

of tragus and the zygomaticofrontal suture, and 25.2 ± 3.1 mm lateral to the plane (VL) through the zygomaticofrontal suture and perpendicular to the HL (Table 2). On the left side, the distances were 27.3 ± 4.2 mm, 3.3 ± 4.9 mm and 26.1 ± 4.3 mm respectively (Table 3). Using paired *t*-test, no significant difference between the right and left sides.

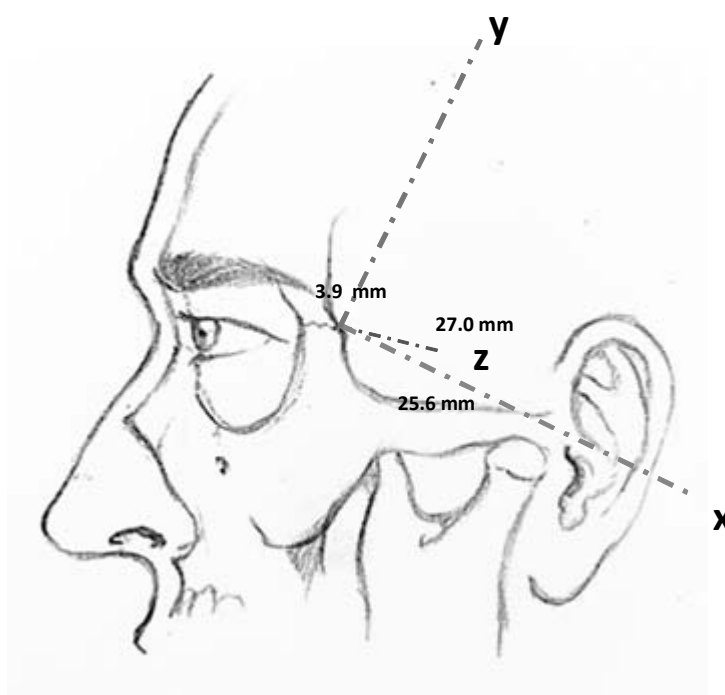


Figure 1. Location of the piercing point of the medial zygomaticotemporal nerve. The X-axis is the plane through the superior edge of tragus and the zygomaticofrontal suture, and the Y-axis, which is perpendicular to the X-axis, is the plane through the zygomaticofrontal suture. Z is the distance from zygomaticofrontal suture.

Table 1. Location of the piercing point of the zygomaticotemporal nerve.

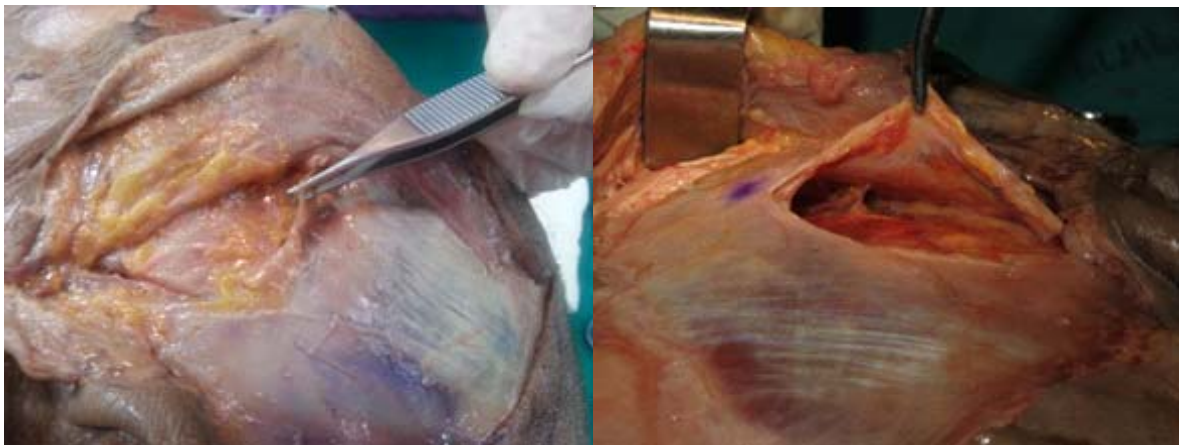
	X	Y	Z
Mean (mm)	25.6	3.9	27.0
SD (mm)	3.7	4.7	3.7

Table 2. Location of the piercing point of the zygomaticotemporal nerve (right side).

	X	Y	Z
Mean (mm)	25.2	4.4	26.7
SD (mm)	3.1	4.6	3.2

Table 3. Location of the piercing point of the zygomaticotemporal nerve (left side).

	X	Y	Z
Mean (mm)	26.1	3.4	27.2
SD (mm)	4.4	4.8	4.2

**Figure 2.** Demonstrating the zygomaticotemporal branch of the trigeminal nerve as it emerges from the deep temporal fascia (left) and exiting temporalis muscle beneath the deep temporal fascia (right).

Discussion

Migraine headache is a chronic and difficult-to-treat condition. Phanthumchinda K, *et al.*⁽⁷⁾ reported that the overall prevalence of migraine in one community in Bangkok was 29.1%. Most of the migraineurs are young adults and more are women. The peak age of the onset of migraine was in the second and third decades. Migraine headache not only has a severely limiting effect on the patient's life, but it also decreases the performance and

productivity of the patients. Researchers have been investigating the role of the trigeminal nerve compression as a cause of migraine headache. Surgical decompression of the nerve has led to successful outcomes in terms of amelioration or complete elimination of migraine headaches in these patients whose treatment was guided by chemodenervation of the muscles surrounding the nerve.

In all 12.5 to 25 units of botulinum toxin A diluted in 0.5 cc of saline was used as chemo-

denervation of the muscles surrounding the nerve.⁽⁸⁾ Because it diffuses in a radius of only 1.5 cm, knowing the site of emergence of the zygomaticotemporal branch of the trigeminal nerve from the temporalis muscle is essential in using botulinum toxin A injection as a predictor for successful surgical outcome.

This study was conducted to identify the emergence point of the zygomaticotemporal branch of the trigeminal nerve from the deep temporal fascia to more easily located the nerve during surgery and to provide a reliable topographic reference for injection of botulinum toxin A. The result from this study shows that the zygomaticotemporal nerve emerges from the deep temporalis fascia in rather a constant location. Regard to this study, detailed anatomical information will enhance the safety and effectiveness of migraine surgery and botulinum toxin A injection treatment.

Totonchi A, *et al.*⁽⁹⁾ and Janis JE, *et al.*⁽¹⁾ described the detailed anatomy of zygomaticotemporal branch of the trigeminal nerve. They found that the main zygomaticotemporal branch of the trigeminal nerve was on average 16.9 mm (range, 12 to 31 mm) posterolateral to the palpebral commissure and 6.5 mm (range, 4 to 11 mm) cephalad to the lateral palpebral commissure.

Although a number of authors have conducted studies to elucidate the anatomical information zygomaticotemporal branch of the trigeminal nerve, most of the studies were performed in Caucasian subjects. No studies had been conducted in Thai population. There is one study in Asians from Hwang K, *et al.*⁽¹⁰⁾ from Korea that delineates zygomaticotemporal nerve passage but the focus was more on the nerve passage in the orbit and the temporal area beneath the temporalis muscle, not above the muscle.

There are also some limitations of this study, however. First, the sample size (n = 24) is too small to be divided into male and female subgroups. Second, most of the cadavers are elderly which are not in the same age group as most of the migraine sufferers. Lastly, soft-tissue change in cadavers renders the use of more noticeable soft-tissue landmarks (such as lateral palpebral commissure) less reliability. Therefore, we have to use a more constant bony landmark (zygomaticofrontal suture) as a reference point.

Conclusions

The nerve responding to the temporal trigger site in migraine headache is the zygomaticotemporal branch of the trigeminal nerve. Surgical decompression or chemo-denervation of the surrounding temporalis muscle can help alleviate the symptoms of migraine headache symptoms. Advances in the understanding of detailed anatomical information will enhance the safety and effectiveness of migraine surgery and botulinum toxin A injection treatment. Study in live Thai adult subjects may be needed in the future to provide more accurate detailed anatomy of the zygomaticotemporal nerve.

Acknowledgement

We gratefully thank Dr. Kanyapa Rerk-ngarm for an illustration shown in this paper.

References

1. Janis JE, Hatef DA, Thakar H, Reece EM, McCluskey PD, Schaub TA, *et al.* The zygomaticotemporal branch of the trigeminal nerve: Part II. Anatomical variations. *Plast*

- Reconstr Surg 2010;126:435-42.
2. Guyuron B, Tucker T, Davis J. Surgical treatment of migraine headaches. *Plast Reconstr Surg* 2002;109:2183-9.
 3. Janis JE, Barker JC, Javadi C, Ducic I, Hagan R, Guyuron B. A review of current evidence in the surgical treatment of migraine headaches. *Plast Reconstr Surg* 2014;134:131S-41S.
 4. Guyuron B, Kriegler JS, Davis J, Amini SB. Comprehensive surgical treatment of migraine headaches. *Plast Reconstr Surg* 2005;115:1-9.
 5. Liu MT, Armijo BS, Guyuron B. A comparison of outcome of surgical treatment of migraine headaches using a constellation of symptoms versus botulinum toxin type A to identify the trigger sites. *Plast Reconstr Surg* 2012;129:413-9.
 6. Guyuron B, Tucker T, Kriegler J. Botulinum toxin A and migraine surgery. *Plast Reconstr Surg* 2003;112:171S-3S.
 7. Phanthumchinda K, Sithi-Amorn C. Prevalence and clinical features of migraine: a community survey in Bangkok, Thailand. *Headache* 1989;29:594-7.
 8. Behmand RA, Tucker T, Guyuron B. Single-site botulinum toxin type a injection for elimination of migraine trigger points. *Headache* 2003;43:1085-9.
 9. Totonchi A, Pashmini N, Guyuron B. The zygomaticotemporal branch of the trigeminal nerve: an anatomical study. *Plast Reconstr Surg* 2005;115:273-7.
 10. Hwang K, Suh MS, Lee SI, Chung IH. Zygomaticotemporal nerve passage in the orbit and temporal area. *J Craniofac Surg* 2004;15:209-14.